

Achilles Tendon Injuries And Repair: An Overview

¹Mohammed Ali Alorayyidh, ²Wail Akel Alkhalidi, ³Naif Ahmed Almutairi,
⁴Emad mobarak allehyani, ⁵Abdullah Mohammed Alrubaie,
⁶Hameed Mohammed A Alshehri

Abstract: The Achilles tendon (AT) is the strongest and thickest tendon in the body. It serves a fundamental function of linking the soleus and gastrocnemius muscles to the calcaneus bone to enable plantar flexion about the ankle joint. We aimed by this recent study to overview the Achilles tendon injuries in different aspects, we intended to examine the causes and risk factors and diagnosis of this condition, However the main purpose of this study was to evaluate the treatment repair approaches to Achilles tendon injuries. Computerized search of the literature in the MEDLINE, CINAHL, and EMBASE databases was conducted December, 2016. The MESH search terms for MEDLINE are: “Achilles tendon” AND “tendon injuries OR tendinopathy” Combined with “treatment OR repair”, with limits for English language and humans. Safe tendon repair work fixation is necessary to avoid gapping and permit a sped up rehab. Selection of the stitch material and knotting method is likewise important to prevent tendon repair separation.

Keywords: Achilles tendon injuries, treatment, MEDLINE.

1. INTRODUCTION

The Achilles tendon (AT) is the strongest and thickest tendon in the body. It serves a fundamental function of linking the soleus and gastrocnemius muscles to the calcaneus bone to enable plantar flexion about the ankle joint. By virtue of its biomechanical homes, the AT affects the capability of numerous human motions ⁽¹⁾. An Achilles tendon injury results from a stretch, tear, or inflammation to the tendon connecting the calf muscle to the back of the heel ⁽¹⁾. These injuries can be painful and so abrupt that they have actually been understood to reduce charging expert football players in shocking style ^(1,2). The most typical cause of Achilles tendon tears is a problem called tendinitis, a degenerative condition brought on by aging or overuse. When a tendon is weakened, trauma can cause it to burst ^(1,2). Achilles tendon injuries are common in middle-aged who may not exercise regularly or take time to stretch effectively prior to an activity ⁽³⁾.

Biopsies recovered at surgery have demonstrated degenerative changes in the majority of ruptured Achilles tendons ⁽⁴⁾, suggesting that Achilles tendon ruptures could be defined as intense injury of chronically degenerated tendons. Rotator cuff disorders are the most common reasons for shoulder disability and are very common in the aging population ⁽⁵⁾. Full-thickness rotator cuff tears exist in around 13% of people in their 50s ⁽⁶⁾, 25% of people in their 60s and 50% of individuals in their 80s ⁽⁵⁾. The etiology of rotator cuff tearing is likely and multifactorial a mix of age-related degenerative modifications ⁽⁷⁾ and micro/macrotrauma. Age, smoking cigarettes, family, and hypercholesterolemia history have actually been revealed to incline individuals to rotator cuff tearing ⁽⁵⁾. Several treatment and repairs options for Achilles tendon injuries, however in cases of postponed medical diagnosis the likely success of conservative management may be restricted by an absence of consistency of the tendon ends due to scarring and retraction. Surgical repair work is promoted ⁽⁸⁾. Cases of chronic rupture of the tendoachilles by their very nature will not react to conservative treatment and for that reason will require repair making use of graft ⁽⁹⁾.

Objectives:

We aimed by this recent study to overview the Achilles tendon injuries in different aspects, we intended to examine the causes and risk factors and diagnosis of this condition, However the main purpose of this study was to evaluate the treatment repair approaches to Achilles tendon injuries.

2. METHODOLOGY

Computerized search of the literature in the MEDLINE, CINAHL, and EMBASE databases was conducted December, 2016. The MESH search terms for MEDLINE are: "Achilles tendon" AND "tendon injuries OR tendinopathy" Combined with "treatment OR repair", with limits for English language and humans. The reference lists of all selected publications were inspected to obtain pertinent publications that were not identified in the electronic search. The gray literature, that included publications, posters, abstracts, and conference proceedings, was likewise hand browsed. Full-text short articles were retrieved if the abstract offered inadequate details to develop eligibility or if the short article passed the very first eligibility screening.

3. RESULTS

❖ Clinical presentation of tendon injured patients:

The patient usually presents with pain, failure to weight bear and a clear popping feeling or sound after an episode of activity during which they sustain a forced dorsiflexion of the ankle. The injury can also be sustained throughout eccentric contraction. The patient frequently describes the sensation of being kicked, shot or perhaps bitten on the back of the heel^(10,11). Intense Achilles tendon rupture can readily be discovered on health examination. Plantarflexion of the foot is naturally weak⁽¹¹⁾. The Achilles tendon is best analyzed with the patient kneeling and the feet hanging over the edge of the chair. In this position soft tissues hang off the Achilles tendon like a tent ridge pole and problems can be readily visualised (**Figure 1**)⁽¹⁰⁾. There is regularly a visible problem in the Achilles tendon. This is accompanied by swelling due to peritendinous haematoma.

The flaw in the Achilles tendon is typically palpable with a level of sensitivity of 0.71 and specificity of 0.89. Maffulli compared the sensitivity and uniqueness of the principal medical tests developed to identify Achilles tendon rupture⁽¹²⁾. Particular tests consist of Simmonds or Thompsons' test with sensitivity of 0.98 and uniqueness of 0.93. Lesser recognized are the O'Brien and Copeland tests both with a sensitivity of 0.8. Early reports suggest that approximately 20% of Achilles tendon injuries can be missed by medical assessment alone⁽¹³⁾.

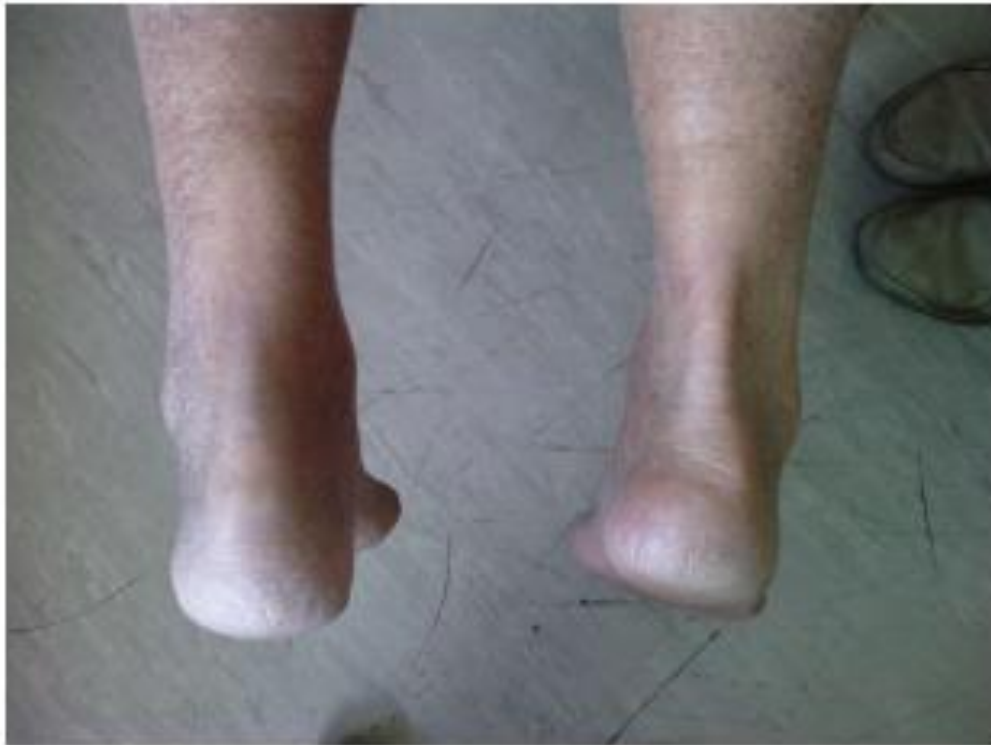

Figure1: View of the right and left Achilles tendon with the patient prone. The left is ruptured. The right Achilles tendon is well defined and soft tissues hang off it like a tent. The suspension of the soft tissues off the Achilles tendon is not visible on the left side as the tendon is ruptured.⁽¹⁰⁾

❖ **Diagnosis of an Achilles tendon injury:**

The accurate diagnosis of an Achilles tendon injury, such as Achilles tendinopathy and, to a lesser degree, Achilles tendon tear, is not always clear and uncomplicated ^(14,15,16). The differential medical diagnosis of an Achilles tendon injury consists of but is not restricted to retrocalcaneal bursitis, ostrigonum, tarsal tunnel syndrome, posterior tibialis tendon rupture, arthritic conditions, plantar fasciitis, and stress fracture ⁽¹⁶⁾.

Diagnostic ultrasound and magnetic resonance imaging (MRI) have actually traditionally been considered the requirement reference requirements to identify Achilles tendon injuries ^(14,15,16). However, this screening can be pricey and might not lead to accurate medical diagnosis ^(17,18,19). Because of restricted proof assistance, the American Academy of Orthopaedic Surgeons' scientific practice guidelines recommendation was undetermined relating to the regular use of MRI for identifying intense Achilles tendon tears ^(19,20,21).

❖ **Treatment (repair) of Achilles tendon injuries:**

Although non-operative treatment can give satisfying results, current research studies have recommended that operative repair work of the AT may have advantages such as reduced ankle stiffness and calf atrophy, fewer cutaneous adhesions, and lower risk of trombophlebitis. For the purpose of this evaluation, it is important to highlight that non-operative treatment cannot avoid tendon lengthening ⁽²²⁾. In a meta-analysis conducted by Khan et al., including 12 randomized control trials and 800 patients, open surgery was related to lower risk of re-rupture than non-operative treatment however higher risk of other issues, particularly wound problems ⁽²³⁾. Surgical treatment appears to be the technique of option for youths, professional athletes, and delayed ruptures. There is no single, evenly accepted surgical method, and the choices include open repair, with or without enhancement, and percutaneous techniques. Minimally invasive and percutaneous techniques have actually been pointed out as valid healing options for AT ruptures. Khan et al. found that percutaneous surgical treatment was related to lower risk of complications than open surgery ⁽²³⁾. That strategy does not permit the surgeon to imagine the ruptured tendon ends and accomplish suitable tendon tensioning ⁽²⁴⁾. In addition, imaging research studies have reported that 100 percent of AT repaired by percutaneous strategy showed residual gap on MRI at 4 weeks postoperative ⁽²⁶⁾. New minimally invasive methods for AT repair may permit direct visualization of the two ends and have actually been reported satisfactory clinical results ⁽²⁴⁾.

Surgical Factors Influencing Tendon Tension Repair:

Secure soft-tissue fixation is essential to numerous clinical applications, from direct tendon repair to tendon transfers to ligament and tendon reconstructions. It allows for early rehabilitation prior to biological recovery, which is vital to numerous procedures. Due to the fact that elongation of the graft might be associated with functional construct failure ⁽²⁶⁾, minimizing elongation of the sutured tendon construct is a vital element of soft tissue fixation.

Biomechanical characteristics of the tendon repair depend mainly on three factors: the quality of the tissue, the strength of the knot, and the strength of the stitch material itself. The quality of the tissue impacts the "coefficient of friction," which is the holding capacity of the suture within the tendon. This is an important idea due to the fact that the failure of the tendon repair work usually occurs due to pull-out of the suture material within the tendon; knot failing was also observed, while suture damage is unusual ⁽²⁷⁾. Suggestions to reduce tendon extending throughout Achilles tendon repair are summed up in (Table 1) ⁽²⁸⁾.

Table1: Summary of recommendations to reduce tendon lengthening during Achilles tendon repair ⁽²⁸⁾

1. Free proximal and distal adhesions
2. Use large caliber (\geq #2) non-absorbable braided suture materials (i.e. polyblend)
3. Use locking suture techniques (i.e. Krackow)
4. Sutures should be place at approximately 2.5 cm from the rupture site
5. Knots should be tied away from the rupture site (i.e. "gift-box technique")
6. Epitendinous suture augmentation is recommended

Suture Technique to better influence the tendon healing:

There are a variety of stitch methods described for grasping and holding soft tissues. When repairing tendons, the Kessler and Bunnell stitches are well-known for their holding power and are frequently used. In 1986, Krackow et al. ⁽²⁹⁾ described a new locking stitch for fixing tendons and ligaments. The traditional Krackow stitch includes three or more locking loops put along each side of the tendon. Watson et al. ⁽³⁰⁾ demonstrated that the Krackow locking repair is stronger than Bunnell and Kessler strategy, developing that the Krackow technique is the benchmark biomechanically. Extra studies confirmed the exceptional pull-out strength of locking loop methods. McKeon et al. ⁽³¹⁾ found that load to failure is significantly increased by including a 2nd interlocking Krackow stitch positioned 90° to the first. They likewise reported that including more than 2 locking loops did not increase load to failure or regularly alter elongation. Using only 2 locking loops not only conserves important operative time however also avoids potential necrosis and injury of the tendon restricted by the loops of the stitch. Extra unnecessary stitch loops will add more links in the chain, more nonlinear sutures, and maybe increase the risk of extending through slippage.

The site where the knot is tied is also of value when thinking about tension restoration. When the knot is connected away from the rupture site, 2 different research studies have reported higher repair work strength. Jaakkola et al. ⁽³²⁾ discovered that the triple bundle is almost three-fold stronger in tension than the Krackow locking loop; this distinction is generally due to the increased number of strands crossing the rupture site. Another consideration this difference is that the knot was tied far from the rupture site in the triple bundle method, whereas in the Krackow strategy, the knot is connected at the rupture site. Having the knot at the rupture site might establish a tension riser on the stitch at the rupture site, and subsequent stress on the suture might lead to early failure at the knot. More recently, Labib et al. ⁽³³⁾ tested a modification of the Krackow technique in which the knots of the stitch were tied over the cross-limb of the counter stitch ("gift-box" method) (**Figure 2**) and discovered that the load to failure increases more than two-fold. The authors thought about that the "gift-box" method is a simple a relatively fast method without constricting additional tissue during the repair work as reported in the "triple package strategy." ⁽²⁸⁾

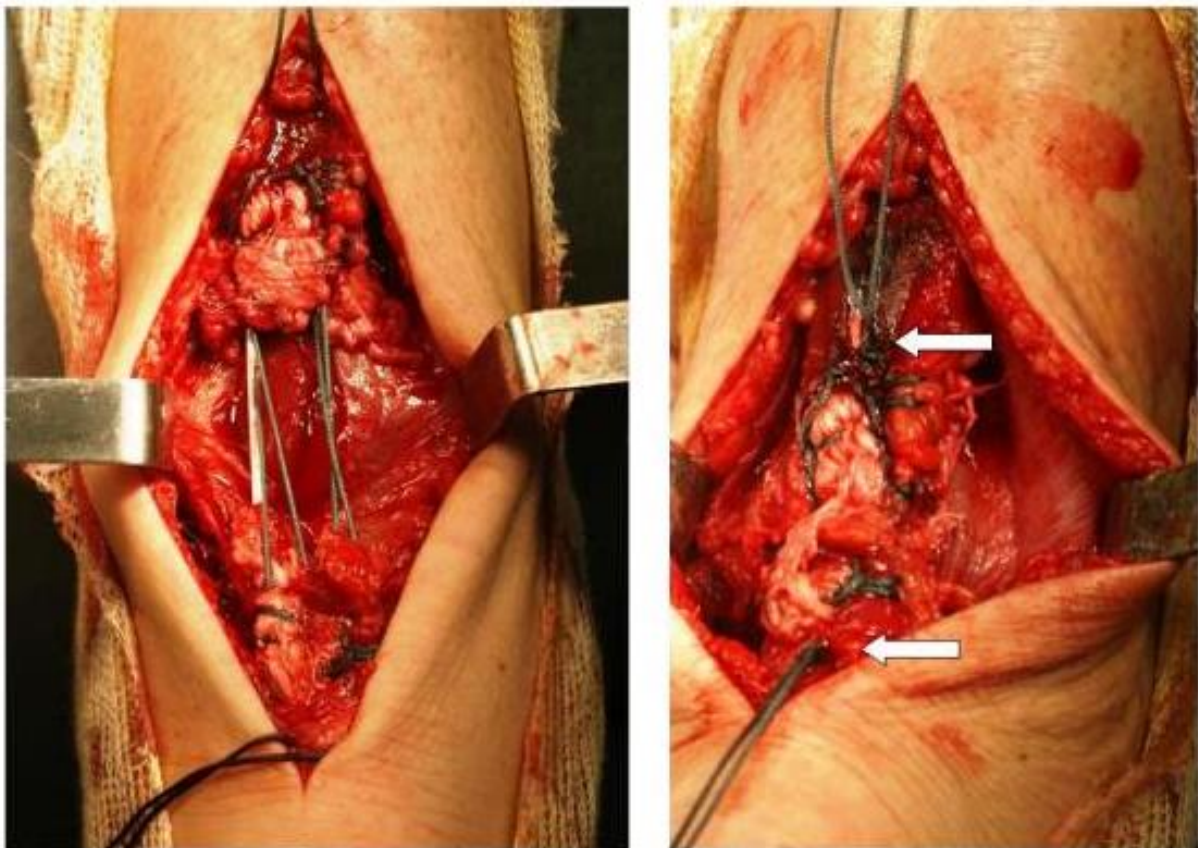


Figure 2: The "Gift-box" technique for Achilles tendon repair. Sutures are tied away from the rupture site (arrows). ⁽²⁸⁾

4. CONCLUSION

Achilles tendon rupture is a serious injury for which the best treatment is still questionable. The surgeon needs to examine a patient's practical requirements thoroughly and treatment need to attempt an optimum restoration of tendon length, tightness, and tension. For that reason, in attempting to avoid excessive elongation of the tendon, which is related to a poor clinical outcome, there is consensus that personnel treatment is the preferred healing alternative for most of patients, specifically young athletes. Safe tendon repair work fixation is necessary to avoid gapping and permit a sped up rehab. Selection of the stitch material and knotting method is likewise important to prevent tendon repair separation.

REFERENCES

- [1] Bressel E, McNair PJ. Biomechanical behavior of the plantar flexor muscle tendon unit after an Achilles tendon rupture. *Am J Sports Med.* 2001;29(3):321–326.
- [2] Jarvinen TA, Kannus P, Maffulli N, et al. Achilles tendon disorders: etiology and epidemiology. *Foot and ankle clinics.* 2005;10:255–266.
- [3] Raikin SM, Garras DN, Krapchev PV. Achilles tendon injuries in a United States population. *Foot & ankle international/American Orthopaedic Foot and Ankle Society [and] Swiss Foot and Ankle Society.* 2013;34:475–480.
- [4] Astrom M, Rausing A. Chronic Achilles tendinopathy. A survey of surgical and histopathologic findings. *Clin Orthop Relat Res.* 1995;(316):151–164.
- [5] Tashjian RZ. Epidemiology, natural history, and indications for treatment of rotator cuff tears. *Clin Sports Med.* 2012;31:589–604.
- [6] Tempelhof S. Age-related prevalence of rotator cuff tears in asymptomatic shoulders. *J Shoulder Elbow Surg.* 1999;8:296–299.
- [7] Longo UG, Franceschi F, Ruzzini L, et al. Histopathology of the supraspinatus tendon in rotator cuff tears. *Am J Sports Med.* 2008;36:533–538.
- [8] Den Hartog BD. Surgical strategies: delayed diagnosis or neglected achilles' tendon ruptures. *Foot Ankle Int.* 2008;29:456–463.
- [9] Maffulli N, Ajis A, Longo UG, Denaro V. Chronic rupture of tendo Achillis. *Foot Ankle Clin.* 2007;12:583–596, vi.
- [10] Gulati V, Jaggard M, Al-Nammari SS, et al. Management of achilles tendon injury: A current concepts systematic review. *World Journal of Orthopedics.* 2015;6(4):380–386. doi:10.5312/wjo.v6.i4.380.
- [11] Saxena A, Bareither D. Magnetic resonance and cadaveric findings of the “watershed band” of the achilles tendon. *J Foot Ankle Surg.* 2001;40:132–136.
- [12] Maffulli N. The clinical diagnosis of subcutaneous tear of the Achilles tendon. A prospective study in 174 patients. *Am J Sports Med.* 1998;26:266–270.
- [13] Saltzman CL, Tearse DS. Achilles tendon injuries. *J Am Acad Orthop Surg.* 1998;6:316–325.
- [14] Maffulli N. The clinical diagnosis of subcutaneous tear of the Achilles tendon: a prospective study in 174 patients. *Am J Sports Med.* 1998;26(2):266–270.
- [15] Jarvinen TA, Kannus P, Maffulli N, Khan KM. Achilles tendon disorders: etiology and epidemiology. *Foot Ankle Clin.* 2005;10(2):255–266.
- [16] Hutchison AM, Evans R, Bodger O, et al. What is the best clinical test for Achilles tendinopathy? *Foot Ankle Surg.* 2013;19(2):112–117.
- [17] Kayser R, Mahlfeld K, Heyde C, Tschauner C. Partial rupture of the proximal Achilles tendon: a differential diagnostic problem in ultrasound imaging. *Br J Sports Med.* 2005;39(11):838–842.
- [18] Kuwada GT. Surgical correlation of preoperative MRI findings of trauma to tendons and ligaments of the foot and ankle. *J Am Podiatr Med Assoc.* 2008;98(5):370–373.

- [19] Kalebo P, Allenmark C, Peterson L, Sward L. Diagnostic value of ultrasonography in partial ruptures of the Achilles tendon. *Am J Sports Med.* 1992;20(4):378–381.
- [20] Kou J. AAOS clinical practice guideline: acute Achilles tendon rupture. *J Am Acad Orthop Surg.* 2010;18(8):511–513.
- [21] Chiodo CP, Glazebrook M, Bluman EM, et al. American Academy of Orthopaedic Surgeons clinical practice guideline on treatment of Achilles tendon rupture. *J Bone Joint Surg Am.* 2010;92(14):2466–2468.
- [22] Soma CA, Mandelbaum BR. Repair of acute Achilles tendon rupture. *Orthop Clin North Am.* 1995;26(2):239–247.
- [23] Khan RJK, Fick D, Keogh A. et al. Treatment of acute Achilles tendon ruptures: a meta-analysis of randomized, controlled trials. *J Bone Joint Surg Am.* 2005;87(10):2201–2210.
- [24] Huffard B, O’Loughlin PF, Wright T, Deland J, Kennedy JG. Achilles tendon repair: Achillon system vs. Krackow suture: an anatomic in vitro biomechanical study. *Clin Biomechanics.* 2008;23(9):1158–1164.
- [25] Fujikawa A, Kyoto Y, Kawaguchi M. et al. Achilles tendon alter percutaneous surgical repair: serial MRI observation of uncomplicated healing. *AJR.* 2007;189:1169–1174.
- [26] Deramo DM, White KL, Parks BG, Hinton RY. Krackow locking stitch versus nonlocking premanufactured loop stitch for soft-tissue fixation: a biomechanical study. *Arthroscopy.* 2008;24(5):599–603.
- [27] Yildirim Y, Saygi B, Kara H. et al. Tendon holding capacities of the suture materials used in repairing Achilles tendon rupture. *Acta Orthop Traumatol Turc.* 2006;40(2):164–168.
- [28] Maquirriain J. Achilles Tendon Rupture: Avoiding Tendon Lengthening during Surgical Repair and Rehabilitation. *The Yale Journal of Biology and Medicine.* 2011;84(3):289-300.
- [29] Krackow KA, Thomas SC, Jones LC. A new stitch for ligament-tendon fixation. *J Bone Joint Surg Am.* 1986;68:764–766.
- [30] Watson TW, Jurist KA, Yang KH, Shen K. The strength of Achilles tendon repair: an in vivo study of the biomechanical behavior in human cadaver tendons. *Foot Ankle.* 1995;16:191–195.
- [31] McKeon BP, Heming JF, Fulkerson J, Langeland R. The Krackow stitch: a biomechanical evaluation of changing the number of loops versus the number of sutures. *Arthroscopy.* 2006;22(1):33–37.
- [32] Jaakkola JI, Hutton WC, Beskin JL. et al. Achilles tendon rupture repair: biomechanical comparison of the triple bundle technique versus the Krackow locking loop technique. *Foot Ankle Int.* 2000;21(1):14–17.
- [33] Labib SA, Rolf R, Dacus R. et al. The “Giftbox” repair of the Achilles tendon: a modification of the Krackow technique. *Foot Ankle Int.* 2009;30(5):410–414.